



## Getting into the x-ray

How pathology changes the grayscale

---

---

---

---

---

### What will I gain from this video?

At the end of the video, you will know about the various ways that pathology can change the normal grayscale on a chest x-ray.

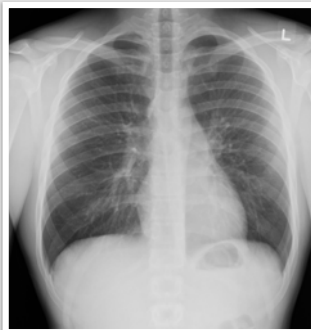---

---

---

---

---




---

---

---

---

---



---


---

---

---

---

---



---

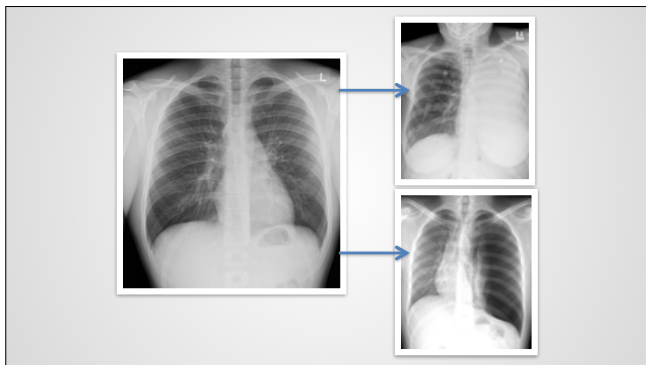
---

---

---

---

---



---

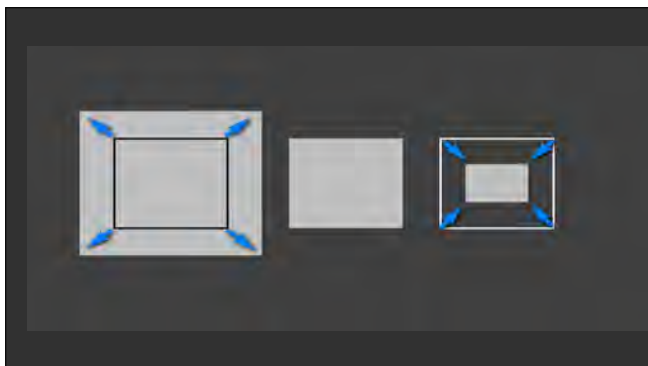
---

---

---

---

---



---

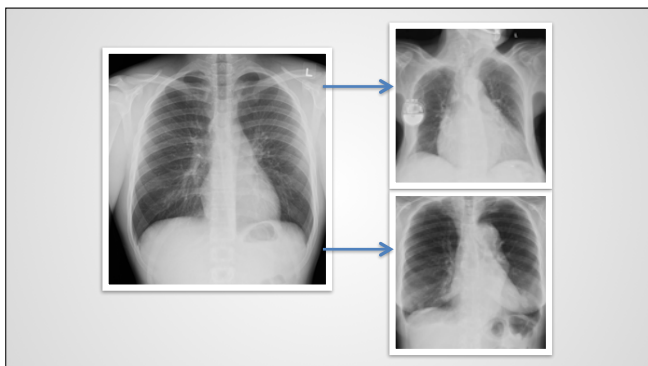
---

---

---

---

---



---

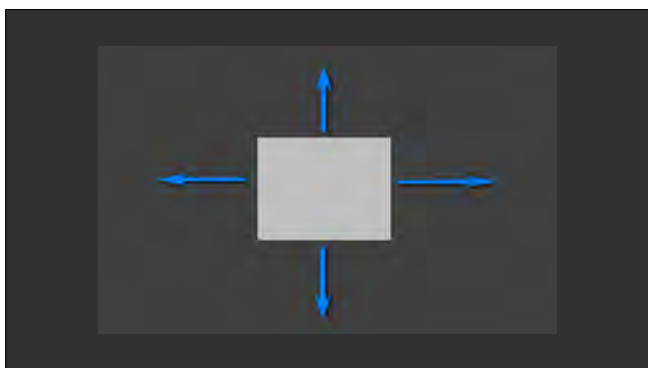
---

---

---

---

---



---

---

---

---

---

---



---

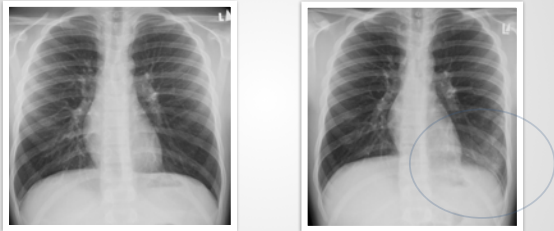
---

---

---

---

**Pre and post series**



---

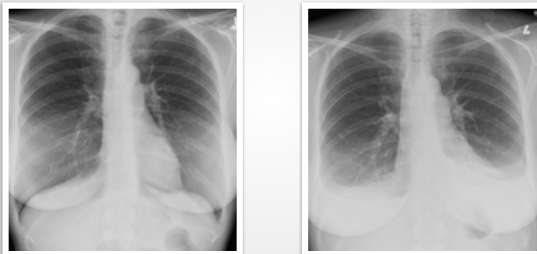
---

---

---

---

**Pre and post series**



---

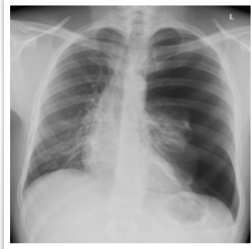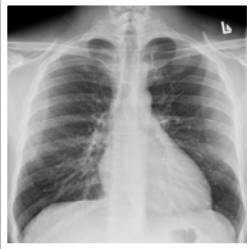---

---

---

---

### Pre and post series



---

---

---

---

---

### Classification of abnormalities:

- Too white
- Too black
- Too black and too white
- Too big
- Too small
- Distorted
- Displaced

---

---

---

---

---